

CHAPTER 19

Ventral and Ventrolateral Spine Decompression and Fusion

Ventral spinal decompression was described by Royle as early as 1928.²⁸ This approach remained unused until 1956 when Hodgson and Stock reported the use of ventral spinal decompression in the treatment of tuberculous lesions.¹⁴ Since then, there has been a progressive increase in the use of ventral and ventrolateral approaches for spinal decompression in treating various spinal lesions such as tuberculosis, pyogenic osteomyelitis, kyphotic deformities, neoplasms (primary and metastatic) and burst fractures.^{5,13,29,30} The types of ventral approaches used for different spinal levels are summarized in Table 19.1 and are discussed in detail in Chapters 9 to 11.

Ventral and ventrolateral decompression principles for spinal tumors are discussed in depth. This is followed by the management of other types of spinal pathology that require ventral decompression.

SPINAL TUMORS

Recently, the surgical management of patients with spinal tumors and associated spinal cord compression has shifted from a laminectomy approach to ventral approaches with ventral decompression.^{5,8,13,33} Because most spinal tumors are located ventrally, a laminectomy can limit the degree of ventral resection and can exacerbate or even worsen existing spinal instability associated with tumors that have destroyed spinal bony segments. Several authors have reported that in most cases, the results of ventral decompression of spinal tumors with spinal cord compression are significantly better when compared with radiation therapy (RT) alone or in conjunction with laminectomy.^{12,39} Dorsolateral approaches can also provide some degree of ventral spinal decompression, with the advantage that they allow for both ventral and dorsal decompression and dorsal stabilization with a single exposure. Because of the limited access of the contralateral ventral dural sac, however, this exposure is more suitable in cases with unilateral spinal canal and vertebral involvement. The results of ventral decompression indicate that this is an effective method to preserve and improve

neurologic function in patients with neural compromise from primary and metastatic tumors of the thoracic and lumbar spine.^{5,13,17,34}

The principal indications for ventral decompressive surgery in patients with ventrally located spinal tumors are (1) intractable spinal or radicular pain; (2) progressive neurologic deficit; (3) metastatic spine lesion without a known primary site (in general, computed tomography [CT]-guided needle biopsy has supplanted ventral decompression for this indication); (4) pathologic fracture with spinal instability; and (5) impending pathologic fracture. In addition, the life expectancy of the patient should be 4 months or greater and the general medical condition of the patient should allow such a procedure to be tolerated. The radiosensitivity of the tumor also needs to be considered when deciding whether ventral decompression or RT should be the initial treatment. Radiosensitive tumors (e.g., lymphoma, myeloma, Ewing's sarcoma, or neuroblastoma) are initially treated with RT if the cord compression is due to epidural tumor alone. With these tumors, surgical decompression is the initial treatment in the following situations: (1) In cases in which spinal cord compression arises from retropulsed bone fragments, spinal deformity, or abnormally aligned spinal segments as a result of bony or ligamentous destruction by tumor; and (2) in cases of failed RT with persistent or recurrent spinal cord compression.

Surgical decompression is the primary treatment for radioresistant tumors (e.g., melanoma or renal cell carcinoma). Tumors of intermediate radiosensitivity (e.g., lung, breast, or prostate tumors) can also be considered for surgical decompression. The decision to opt for RT or surgical decompression as the initial treatment depends on (1) the extent of tumor compression (e.g., multiple-level contiguous-vertebrae involvement may favor RT as the initial treatment) and (2) the degree and rate of progression of the neurologic deficit (e.g., a rapidly progressive deficit is best treated by early surgical intervention in order to prevent further deterioration from the compressive mass).

Table 19.1 Classification of Ventral Surgical Approaches

SPINAL SEGMENT	SURGICAL APPROACH
Cervicothoracic C7–T2 (see Fig. 19.11)	Extended ventral cervical (division of strap muscles) Transsternal Cervicosternotomy (“trapdoor” approach)
Upper Thoracic T2–T5 (see Fig. 19.10) T6–T12 (see Fig. 19.2–19.7 & 19.9)	High dorsolateral thoracotomy (third rib approach with mobilization of scapula) Dorsolateral thoracotomy
Thoracolumbar T12–L2 (see Figs. 19.1 & 19.8)	Transsthoracic/retroperitoneal with tenth to twelfth rib resection; division of diaphragm
Lumbar L2–L5	Retroperitoneal/flank Transabdominal
Lumbosacral L5–sacrum	Ventral retroperitoneal (“pelvic brim” approach)

Preoperative Assessment

Initially, plain spine radiographs (anteroposterior and lateral) are used to determine the spinal level and extent of tumor involvement. The spinal alignment can also be observed from these films. A CT with and without intravenous contrast at the appropriate spinal levels allows the degree of bony destruction of the spinal column to be defined. Although magnetic resonance imaging (MRI) is less precise than CT in outlining bony destruction, it provides the most precise means for illustrating the site and degree of cord compression by tumor or bone (Fig. 19.1). Myelography and postmyelography CT can be used when MRI is not available or is contraindicated.

To avoid complications from intraoperative and postoperative instability of the spinal column, it is important to assess the spinal stability of the spine before performing a vertebral decompression. Stability can be considered in terms of the three-column theory, after the extent of bony destruction produced by tumor has been determined from imaging.^{6,37} Single-column involvement can be considered relatively stable. The additive destabilizing effects of decompression, however, must factor into the decision-making process.

Anterior-column and middle-column involvement are the most common findings in symptomatic patients with spinal tumors and are frequently associated with some degree of vertebral body collapse and bony retropulsion into the spinal canal (Fig. 19.1A). If these conditions are treated by corpectomy, with a strut graft used for fusion (Fig. 19.1 B & C), stability of the spinal column can be achieved.

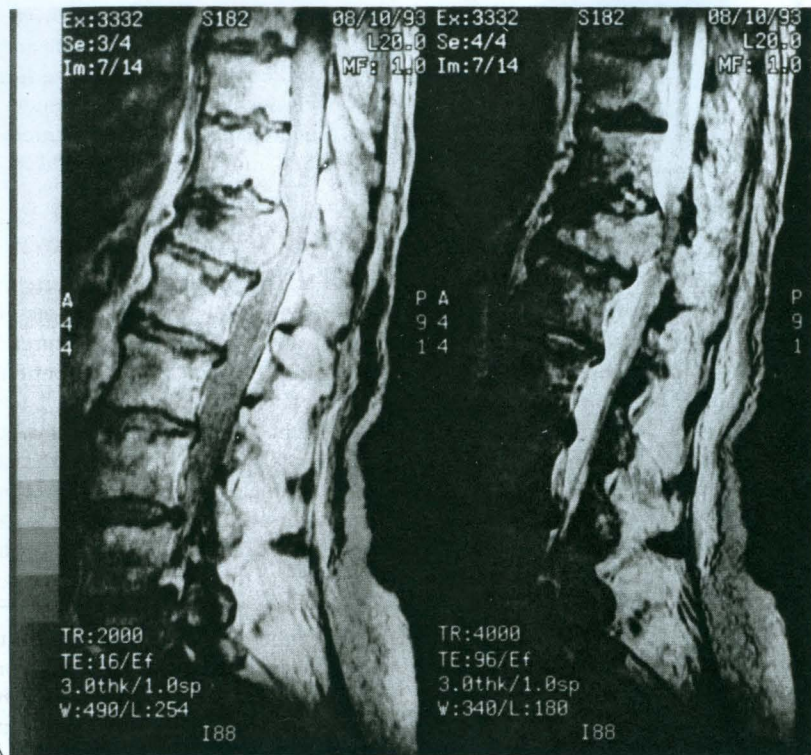
When dorsal elements, in addition to anterior-column and middle-column elements (three-column involvement), show bony destruction, the spinal column is considered highly unstable. This has important implications for subsequent decompression and fusion. Corpectomy and vertebral replacement techniques will result in persistent dorsal element instability. This can prevent subsequent fusion and result in failure of the ventral fixation. To avoid such complications, these cases should also be stabilized dorsally with further dorsal decompression, if necessary.

Assessment of stability, when planning surgery for spinal tumors, must also take into account the presence of angulation and malalignment.³⁷ It is also important to consider the nature of the tumor in terms of its capacity to infiltrate and destroy bony tissue as well as its response to RT or chemotherapy.

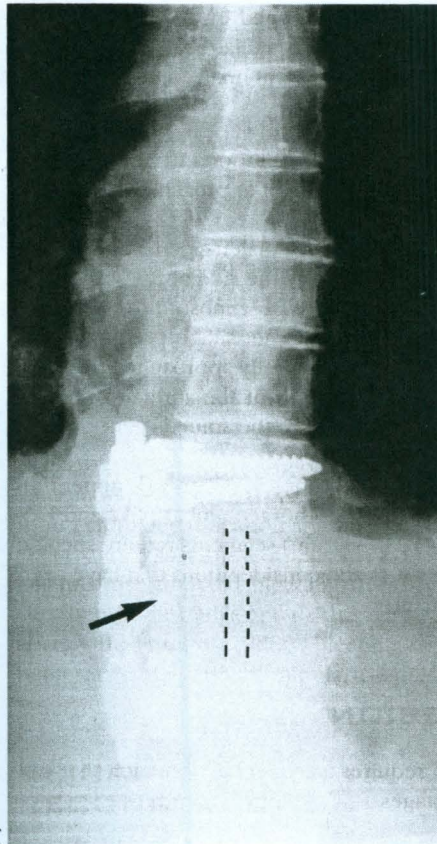
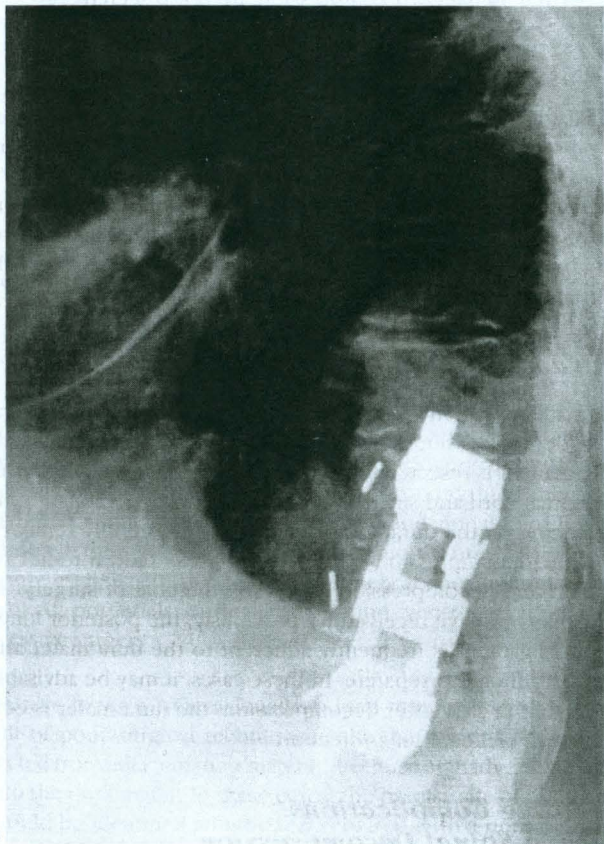
Preoperative Angiography and Embolization

In patients with known vascular tumors (e.g., melanoma, renal cell carcinoma, metastatic thyroid tumor, or primary giant cell tumor) or in patients in whom imaging suggests a relatively vascular tumor, angiography, with a view to embolization, is recommended. If these tumors are amenable to embolization, this should be performed within 48 to 72 hours of surgery.

Figure 19.1 (A) Proton density and T₂-weighted sagittal MRI image of metastatic carcinoma of the breast to the T12 vertebral body with angulation and severe spinal cord compression. **(B & C)** Postoperative lateral and anteroposterior radiographs after T12 vertebral body resection showing the placement of a rib bone graft, methylmethacrylate, and Kaneda instrumentation. Postoperatively, the patient recovered full neurologic function and was pain free. In view of the isolated vertebral body involvement, it was believed that good long-term survival was possible (hence the use of additional bone graft in the reconstruction). The patient, however, died of systemic metastatic cancer 8 months postoperatively.



A



B

C

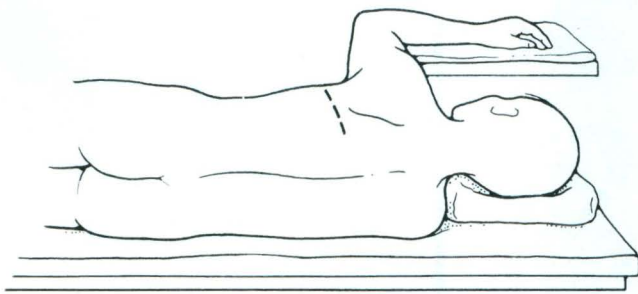


Figure 19.2 Patient is in the lateral position, and a dorsolateral thoracotomy skin incision is placed below the scapula.

Surgical Management

INTRADOPERATIVE MONITORING AND ANESTHETIC MANAGEMENT The authors recommend electrophysiologic monitoring, including somatosensory and/or motor evoked potentials, although the benefits of these techniques have not been definitely proven. In approaches of the upper and middle thoracic spine, a double lumen endotracheal tube allows the lung in the operative field to be deflated, improving the surgical exposure. In lesions of the lower thoracic and thoracolumbar regions, the lung can be easily retracted. Invasive arterial pressure monitoring and CVP monitoring is recommended.

POSITIONING Patients are positioned in the full lateral decubitus position (Fig. 19.2) with an axillary roll placed under the dependent axilla in order to prevent neurovascular compromise.

INCISION AND EXPOSURE Two important factors at this point in the procedure are the side of approach and the level of the spine that is involved.

The decision to perform a right- or left-sided skin incision and approach should be directed by the side of the spine with greater tumor involvement, otherwise exposure to the spinal tumor would be more limited. If neither side is predominantly involved by tumor, the spine is generally approached from the right side in order to avoid the arch of the aorta at or above the T5 vertebral segment. Below T5, the spine is generally approached from the left side.

Lesions involving the cervicothoracic (C7 to T1), upper thoracic (T1 to T5), lower thoracic, thoracolumbar (T12 and L1), and lumbar and sacral (L2 to sacrum) segments require specific approaches (see Table 19.1) and considerations that have been described in earlier chapters.

SPINAL DECOMPRESSION

Spinal decompression requires a sequential approach that can be divided into four stages.

Exposure

The pleura is sharply incised and reflected. A rib head that overlies the level of the pathology in the midaxillary level is resected. The segmental vessels at the level of the pathology and of the vertebral bodies above and below the lesion (Fig. 19.3) are

ligated and divided close to the origin from the aorta. Division of segmental vessels over the vertebral body close to the aorta avoids vascular compromise of the spinal cord resulting from the presence of collateral vessels that anastomose in the neural foramen. The periosteum is reflected medially, and the anterior longitudinal ligament is identified and incised.

Vertebral Body Decompression

The intervertebral discs above and below the involved vertebral body are identified and resected initially by sharp dissection (Fig. 19.4), and further disc material is cleared with curettes and pituitary rongeurs. The ipsilateral pedicle and its continuation into the vertebral body is identified by removing 1 to 2 cm from the head of the rib. The pedicle is an important marker for the orientation and position of the spinal canal. With the use of sharp curettes, rongeurs, and a high-speed drill, the vertebral body is resected ventrally to dorsally, except for a small rim of the ventral portion of the vertebral body. Resection of the vertebral body can progress as far as the opposite pedicle (Figs. 19.5 and 19.6), and the entire dorsal aspect of the vertebral body can be removed. Sufficient bone needs to be removed to clear the posterior longitudinal ligament of any compression. The dissection can also be continued dorsolaterally to allow decompression of the spinal nerve roots. Adjacent segments of vertebrae without evidence of vertebral bony collapse or associated spinal cord compression are not resected.

Rostrocaudal Dissection

Cartilaginous endplates and the central regions of cancellous bone of vertebral bodies adjacent to the corpectomy site are removed using a small high-speed burr or curettes (Fig. 19.7). Osteotomes and rongeurs may also be used depending on the bony consistency. This allows troughs to be created in the vertebral bodies above and below the corpectomy site to allow subsequent reconstruction with a bone graft or acrylic.

Intraspinal Decompression

After adequate bony resection and decompression and removal of all devitalized bone and tumor tissue, the posterior longitudinal ligament is resected to expose the dura mater that encloses the spinal cord and segmental nerve roots. Any tumor or bone impinging on the dural sac or nerve root is carefully removed to allow decompression of these structures. Radical tumor resection and decompression should be the goal of surgery. In patients who have received RT previously, the posterior longitudinal ligament is frequently adherent to the dura mater and may be difficult to separate. In these cases, it may be advisable to leave it in situ. After decompression, the dura mater is covered with Gelfoam for protection.

Avoiding Complications During Spinal Decompression

INADEQUATE SPINAL DECOMPRESSION Inadequate decompression reduces the chance of adequate neurologic recovery and carries the risks of incomplete tumor resection. It is important that the decompression be performed to the contralateral pedicle.

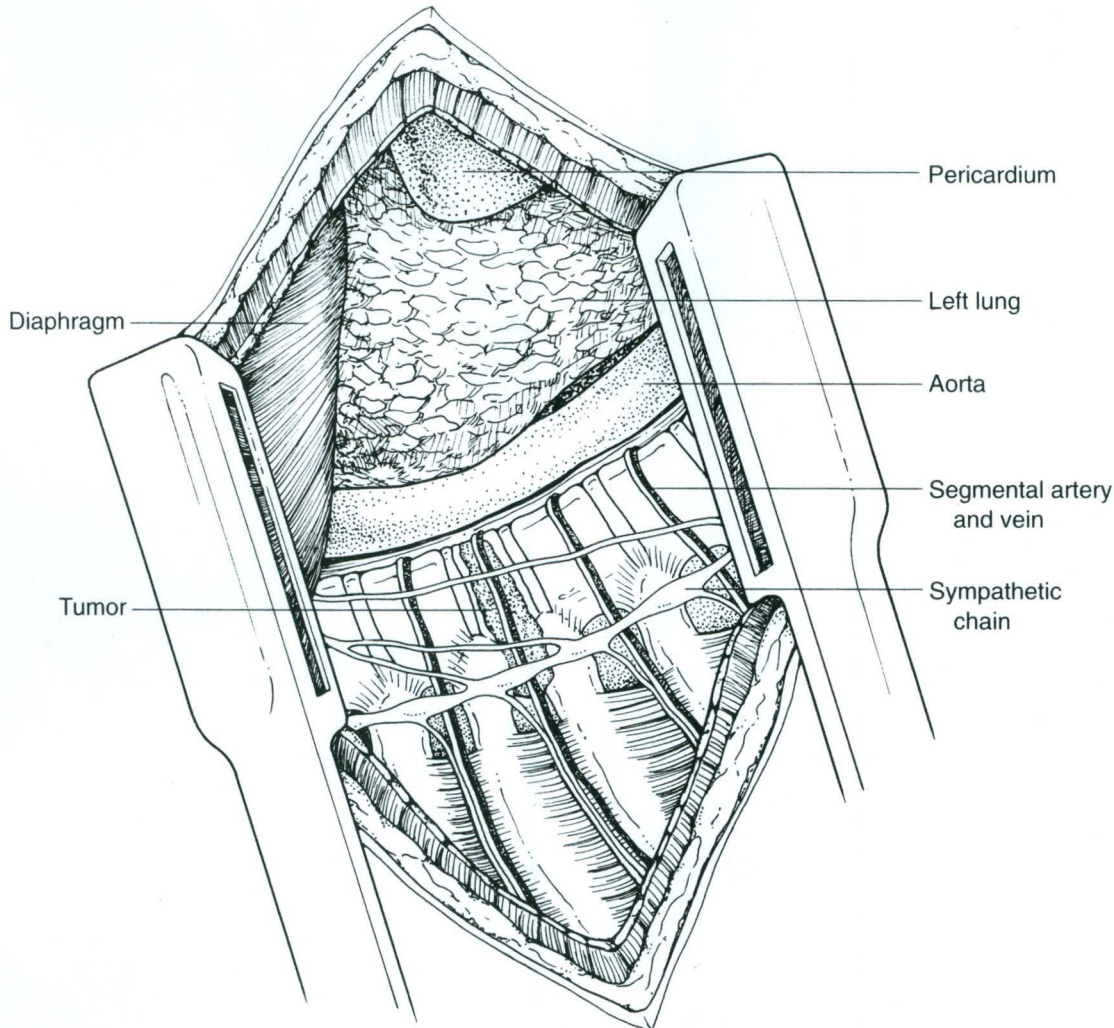


Figure 19.3 Exposure of the thoracic spine after entry into the thoracic cavity and placement of a self-retaining chest retractor. The parietal pleura has been separated from the ribs and spinal column with the segmental vessels along the side of the vertebrae identified.

NEUROLOGIC INJURY A careful, staged approach to spinal decompression as described, with adequate exposure and identification of segmental vessels, nerve roots, and dural tube will markedly reduce the risk of nerve root and spinal cord injury. Although the value of evoked-potential monitoring has not been firmly established, the authors routinely record multimodality evoked potentials during ventral and ventrolateral decompressive surgery.

DURAL TEARS Occasionally a dural tear may occur as a result of poor surgical technique while the tumor is being dissected from adjacent dura mater or because of inadvertent entry into the dura mater. In these cases, the precise site of dural tear should be identified and the tear repaired with a nonabsorbable suture (e.g., 4-0 Neurolon [Ethicon]). In less discrete or poorly visualized dural tears, fibrin glue can be layered over the cerebrospinal fluid leakage site of the dura mater, and subcutaneous fat can be placed over this to allow adherence to underlying dura mater. A lumbar drain should be placed for 5 days postoperatively to facilitate dural closure.

EXCESSIVE EPIDURAL BLEEDING OR BLEEDING FROM TUMOR Preoperative angiography and embolization of vascular tumors reduces the risk of such intraoperative bleeding. After careful identification and mobilization, segmental vessels above and below the corpectomy site should be ligated and cut in order to avoid bleeding from these vessels when the vertebral bodies adjacent to the corpectomy site are spread apart. Other sites of epidural bleeding should be identified and hemostasis attained with bipolar coagulation.

SPINAL RECONSTRUCTION

Graft Material

The decision regarding the type of material to use for spinal column reconstruction depends on the nature of the lesion and the patient's life expectancy. In cases of trauma, for benign lesions, or for patients with malignant tumors who have a rela-

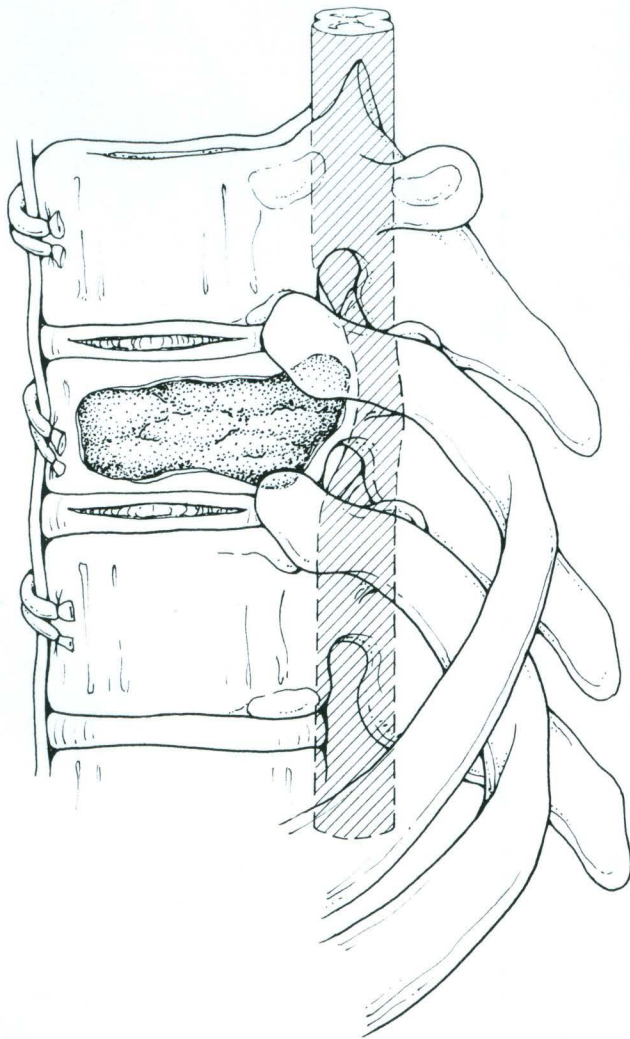


Figure 19.4 After a thoracotomy via resection of a rib located one level rostrally, the pleura is reflected off the ventral spine. The segmental vascular bundles are isolated and ligated as shown. Vertebral decompression of the tumor begins by the excision of intervertebral discs above and below the involved vertebra. Following this, 1 to 2 cm of the rib head is drilled down to expose the ipsilateral pedicle.

tively long life expectancy (greater than 2 years), reconstruction is best performed using autogenous bone from the iliac crest or rib for single vertebral body defects. If two or more vertebral levels are involved with the neoplasm, an allograft (e.g., from fibula or humerus) can be used. It is often useful to supplement allograft with local autograft (Fig. 19.8).

In patients with malignant disease and a short life expectancy, autogenous bone grafts have certain disadvantages. (1) Because life expectancy is usually less than 1 year, solid bony fusion over a long term is unnecessary. (2) The use of adjunctive radiation and chemotherapy will slow or even prevent the bony fusion needed for stability. (3) Any remaining local tumors may infiltrate the bone graft and weaken the construct. (4) Autogenous donor sites may not be suitable because of tumor involvement.

For these reasons, in patients with malignant disease and

short life expectancies (less than 1 year), synthetic constructs using polymethylmethacrylate (PMMA) are used.

Reconstruction Technique

The aim of reconstruction techniques is to provide solid fixation to adjacent spinal segments. Failure of these constructs is usually the result of reconstruction material dislodging at proximal, distal, or both ends at which it fits into adjacent spinal segments. Postoperatively, early spinal changes in the cancellous bone of adjacent vertebral segments, seen on MRI scans, can be an early indication of potential failure of these regions to anchor the construct. Another important situation is one in which adjacent vertebral segments are involved with disease but are not collapsed and are not causing spinal cord compression. PMMA can be used to strengthen the adjacent bone. Alternatively, supplemental dorsal instrumentation may be required.

SYNTHETIC CONSTRUCTS The technique of Errico and Cooper, in which PMMA is pressure injected into a Silastic tube that is fit into the vertebral body defect, is ideally suited for metastatic lesions (Fig. 19.9).⁸ Silastic tubing of varying diameters (typically 15 to 20 mm) is cut to a measured length (from the outer edge of the upper and lower troughs of adjacent vertebral segments to the corpectomy site). One 6-mm-diameter hole is made in the center of the tubing with a rongeur, and three small holes are made laterally, two at the rostral end and one at the caudal end. Small bites are also made at the ends of the tubing to allow extrusion of cement overflow. The three smaller lateral holes allow air bubbles and excess cement to flow out easily. The side of the Silastic tubing facing the spinal cord is free of the central and lateral holes to avoid cement extrusion into the spinal canal. The Silastic tubing is passed into the space between two adjacent vertebral bodies at the corpectomy site and positioned so that there is no bending of the tubing that could obstruct cement flow. Low-viscosity, slow-curing PMMA is prepared and is kept in a large 50-ml syringe, and when it has become semiliquid, the PMMA is injected through the center hole of the Silastic tubing to fill the tubing until PMMA can be seen passing out from the ends of the tube (see Fig. 19.9). The tube must be observed carefully to avoid spilling the PMMA into the spinal canal. Curved Penfield dissectors can be used to protect the dural tube. As the PMMA under the Silastic tubing becomes harder, more PMMA is prepared and placed ventral and lateral to the Silastic tube until it is continuous with the borders of the upper and lower vertebrae. During polymerization and hardening of the PMMA, copious saline irrigation is used to help dissipate the heat. Hemostasis is attained with bipolar coagulation.

Using Silastic tubing instead of K-wires, in conjunction with PMMA, for reconstruction of the vertebral body defect has certain advantages: First, the pliable Silastic tubing can be positioned with its ends sitting against the graft beds of rostral and caudal adjacent vertebrae. This ensures that the tubing is anchored against the adjacent vertebral bodies and does not remain unanchored in an open defect, thus reducing the risk of extrusion of the cement into the spinal canal and enhancing fixation to the adjacent vertebral column. Second, passing PMMA into the cancellous bone of adjacent vertebral segments further reinforces the vertebral bodies above and below the

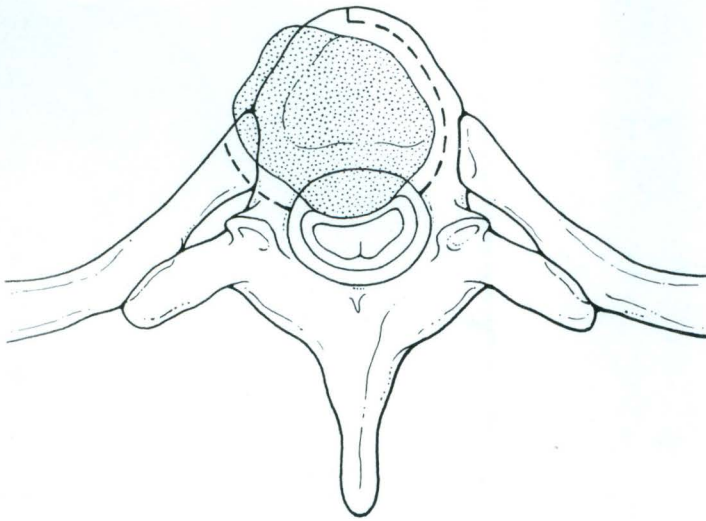


Figure 19.5 Axial section through vertebra involved with spinal tumor showing the extent of bony decompression necessary to allow adequate tumor resection.

corpectomy site. Third, the pliable plastic with hardened PMMA becomes a long rigid construct that encompasses the length of the corpectomy site defect to allow anchorage into adjacent vertebrae. This reduces the risk of the construct dislodging from this position.

Degree of Vertebral Involvement

Most forms of metastatic spinal disease usually involve the vertebral body. When there is significant involvement of the dorsal elements, dorsal resection of the dural sac can be performed by laminectomy as the second stage of a ventral procedure (performed at the same time or at a later date). In these cases, supplemental dorsal instrumentation is recommended to prevent subsequent spinal instability, spinal deformity, or excessive spinal movement that may predispose to loosening and dislodgment of the spinal construct at the corpectomy site. The

authors' preference is to use universal fixation rods extending three levels above and two levels below the corpectomy site.

BONY GRAFT FUSION IN MALIGNANT AND NONMALIGNANT DISEASE

In patients with nonmalignant disease or with malignant disease with a relatively longer survival period (usually greater than 2 years), a bone graft is used to supplement the synthetic construct described above (see Fig. 19.1).

Fusion

DISTRACTION After initial vertebral decompression, vertebral distraction is attained by using a vertebral distracter or by applying distraction after placing vertebral screws.

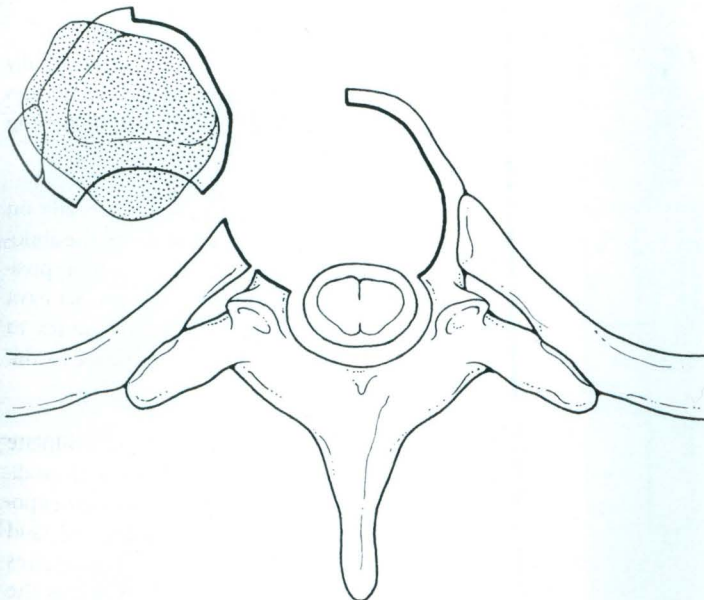


Figure 19.6 Remaining vertebra after bony decompression and tumor removal showing that the decompression extends from the ipsilateral pedicle to the contralateral pedicle.

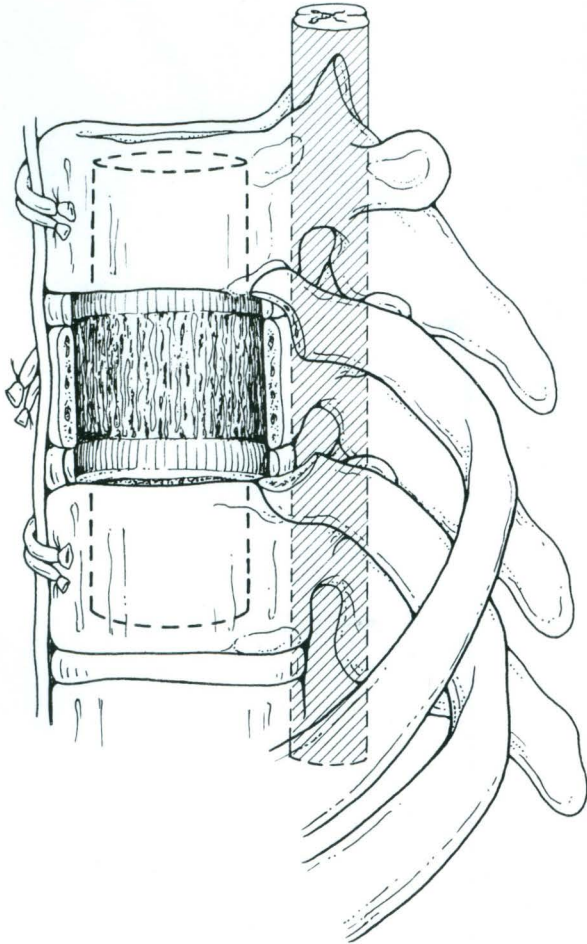


Figure 19.7 After tumor resection, the end-plates and cancellous bone of adjacent vertebral bodies are removed to the degree shown (dotted line) using an angled high-speed drill or angled curettes.

GRAFT SITE PREPARATION The end-plates of vertebral bodies adjacent to the decompression site are prepared to accept a graft. The underlying cancellous bone should not be exposed by complete removal of the endplates because this will reduce the mechanical supporting ability of the vertebral body and increase the risk of the graft penetrating the weakened vertebral bodies. The rostral and caudal endplates are of different shapes. This must be borne in mind with selective drilling to ensure that the graft site has parallel surfaces with adequate cortical bone remaining to support the graft. One common mistake is the failure to remove sufficient ventral and dorsal lip, resulting in a central gap between the bone graft and vertebral endplate. Another mistake that has more serious consequences is the "ramp effect" that occurs when excessive bone is removed from the ventral two-thirds of the lower vertebral body. This results in a graft site that is longer ventrally than dorsally, predisposing to ventral dislocation of the graft.

Grafting

A firm, well-fitted graft is the result not only of a well-prepared graft site but also of a well-proportioned, appropriately sized bone graft. A caliper and a depth gauge should be used to mea-

sure the length and depth of the graft site accurately in order to determine the dimensions of the bone strut. The depth of the graft site is measured from the dorsal cortex to the ventral cortex along the midline of the vertebral body. The length of the graft site is measured with the vertebral bodies maximally distracted and is the distance between the endplates.

A tricortical iliac crest bone graft can be used up to a two-level corpectomy. More extensive decompressions may necessitate the use of a humeral or fibular allograft. Such an allograft strut has greater biomechanical strength than iliac crest, with a fusion rate similar to that of autologous bone, although the high cortical bone content means that it may take up to a year for the graft to incorporate.² A supplemental local autograft (e.g., from rib or vertebral body) will enhance the rate of fusion when using allografts (see Fig 19.8). If grafts are taken from the iliac crest, the osteotomies should be perpendicular to the surface of the iliac crest and parallel to each other. A double-bladed oscillatory saw is useful in obtaining parallel surfaces. When these grafts are to be used for subtotal or total vertebral body replacement, several extra millimeters should be taken to allow for further reshaping. In the midthoracic and upper thoracic spine, rib strut grafts taken at the time of the thoracotomy are usually adequate.

The graft is tamped into position with the vertebral bodies distracted and should fit without excessive force or hammering. The position of the graft should be checked by placing a blunt hook alongside the graft. Small pieces of cancellous bones can be gently impacted into the remaining gaps. However, care should be taken to avoid spinal canal compromise or compression of neural structures by these smaller pieces of bone. It is important to remove any irregularities of the anterior surface of the vertebral bodies with a drill so that the plate can sit flush up against them. A greater plate-to-bone contact allows increased structural stability of this construct.

Avoiding Complications Related to Fusion

Specific complications relating to fusion are an important consideration for reducing the morbidity that can be associated with this procedure.

HEMORRHAGE Although hemorrhage cannot be totally avoided, it is important to minimize the amount of blood loss during fusion, by giving special consideration to the following three factors.

POSITIONING Care in positioning the patient correctly on the operating table will avoid unnecessary pressure on the abdomen. This is particularly relevant in the lateral or prone positions and is thought to be related to a reduction in vena cava obstruction, which allows veins in the lower extremities to drain into the inferior vena cava and not be diverted to the paravertebral plexus.

TIMING OF ENDPLATE PREPARATION Because endplate preparation and decortication may be associated with additional blood loss, this should only be done after the bony exposure has been completed, soft tissue has been excised, and bone graft has been harvested. Bleeding from decortication sites should not be treated with bone wax because this reduces the

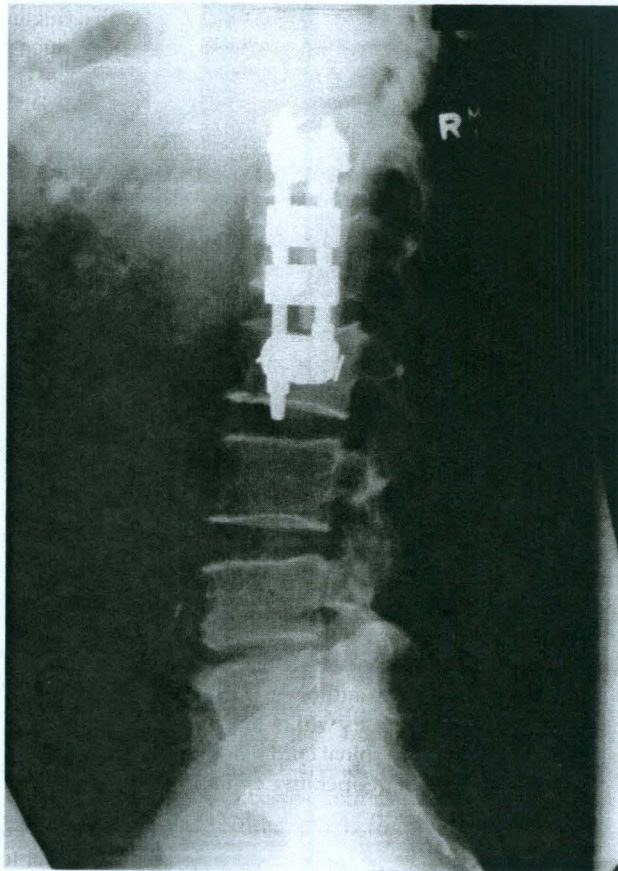
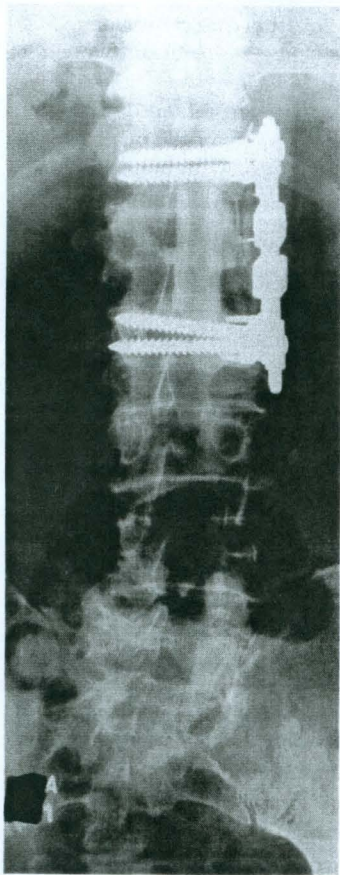
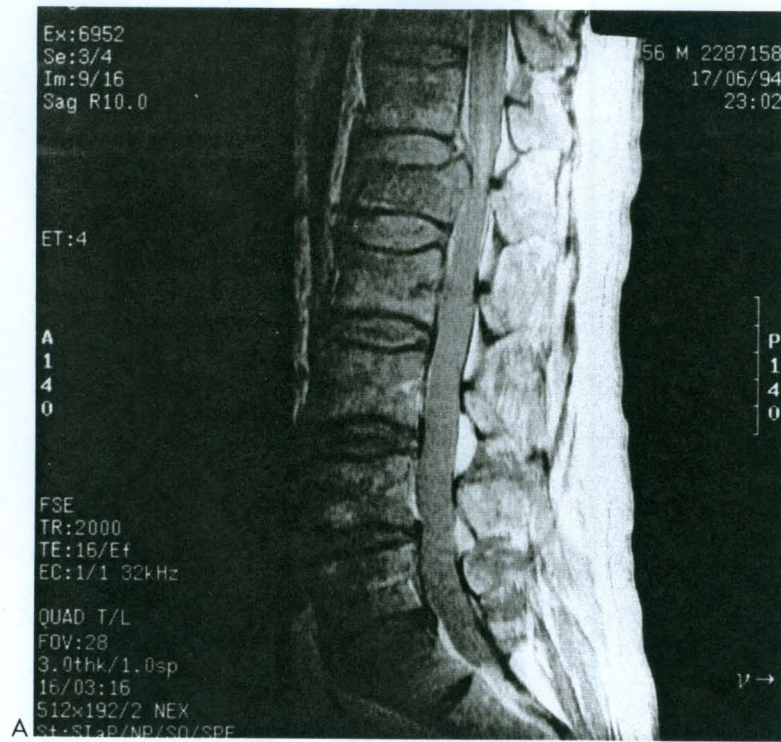


Figure 19.8 (A) Proton density sagittal MRI scan illustrating an L1 burst fracture with compression of the conus. (B & C) Postoperative anteroposterior and lateral radiographs after anterior decompression and stabilization using bone graft (combination of humeral allograft and rib autograft) and Kaneda instrumentation.

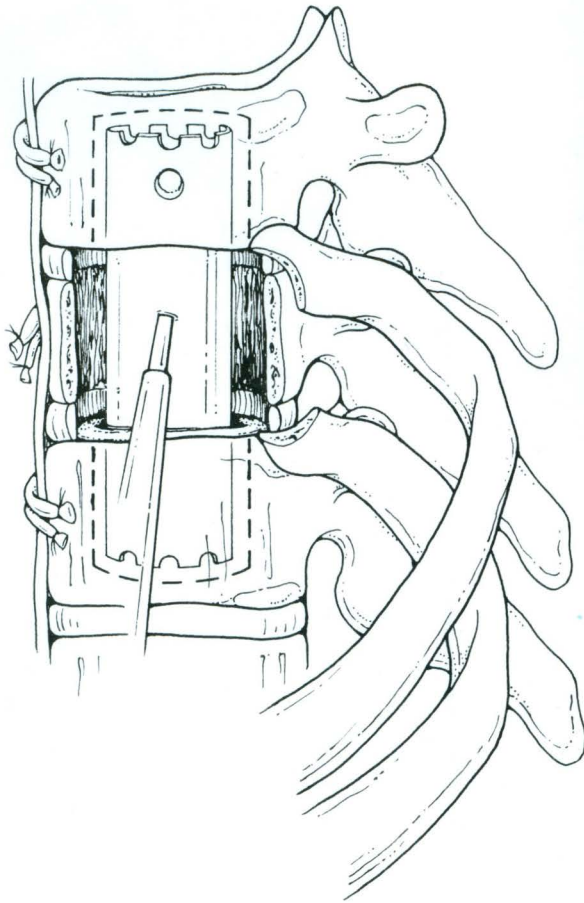


Figure 19.9 After the Silastic tubing is inserted into the spinal defect, a syringe is used to fill the tube with slow-curing, low viscosity polymethylmethacrylate.

capacity for osteogenesis.¹⁰ Excessive bleeding may be controlled with Gelfoam, and it usually settles after the graft is inserted.

SEGMENTAL VESSELS To avoid inadvertent injury and excessive bleeding, the segmental vessels should be clearly identified and dissected so that they may be suture ligated and divided in a controlled safe manner. In the lower thoracic and upper lumbar region, the artery of Adamkiewicz and other radicular arteries supplying the anterior and posterior spinal arteries can be identified by preoperative selective segmental vessel angiograms in instances in which there is a concern that these vessels may be at risk during the approach. The authors usually reserve preoperative spinal angiography for cases with a longstanding fixed kyphotic deformity in which the spinal cord blood supply may be tenuous or for cases in which preoperative embolization is desired.

PSEUDARTHROSIS Pseudarthrosis refers to a lack of bony union and may account for a clinically poor result. It must also be remembered, however, that fibrous pseudarthrosis may limit spinal movement and allow a good clinical outcome with symptomatic relief. Moreover, even when bony fusion has occurred, patients can remain symptomatic. Meticulous attention to graft

site preparation and use of autograft where possible enhances fusion rates. In cases of traumatic lesions, the supplementation of the fusion with local vertebral body autograft that is osteoinductive may be appropriate.

HARVESTING AUTOGENOUS ILIAC CREST BONE The iliac crest is the most common site from which bone grafts are taken. Consideration of the following complications during this procedure may help reduce the donor site morbidity that may be associated with this procedure.¹⁸ Donor site pain is common, can continue for more than 3 months, and is related to the degree of dissection.

Cosmetic deformity is a problem that is associated with a full-thickness graft taken from the crest and that affects the crest contour. When larger grafts are taken and cosmetic deformity becomes a concern, three techniques are useful in preventing crestal deformities: (1) the trapdoor method uses the crest as a hinge, (2) the subcrestal window avoids resection of the rostral margin of the crest; and (3) oblique sectioning of the crest allows the crest to be reconstituted.³⁸

Although infection is not a major concern, it does occur occasionally. A deep wound infection at the iliac donor site is treated like other wound infections adjacent to bone, because it will require drainage, irrigation, and appropriate antibiotic coverage.

Hematoma is not uncommon at the wound site. Gelfoam or bone wax can be used, but microcrystalline collagen is best for reducing bleeding from cancellous bone.⁵ Suction drainage may reduce the incidence of significant wound hematomas to less than 1 percent.

Gait disturbance with a limp or abductor lurch as a result of considerable stripping of the outer table muscles can cause hip abductor weakness. With bone graft taken from the dorsal crest, patients may have difficulty with hip extension, which is evident when climbing stairs or rising from a chair.

Stress fractures can occur after full-thickness grafts are taken from the anterior iliac crest. Stress fractures, as a result of the pull from the sartorius and rectus femoris muscles, can be avoided by harvesting the graft well away from the anterior superior iliac spine. Moreover, taking long strips of bone along the iliac crest increases the risk of ilium fracture.

Perforation of the peritoneum can occur with a ventral approach to the inner table of the iliac crest because the peritoneum is closely related to the inner surface of the abdominal wall and iliacus muscles. Herniation of abdominal contents can occur after removal of full-thickness grafts that include the iliac crest.

Injury to the lateral femoral cutaneous nerve of the thigh can be avoided by placing the skin incision and continuing the dissection well behind the anterior superior iliac spine, because this nerve passes under the inguinal ligament immediately ventral to it.

INSTRUMENTATION

The need for supplementary instrumentation depends on the spinal level involved and the degree of bony involvement.

T1 to T9

When the corpectomy involves the thoracic spine alone, supplementary instrumentation is generally not necessary because the thoracic spine, unlike the lumbar spine, is supported by

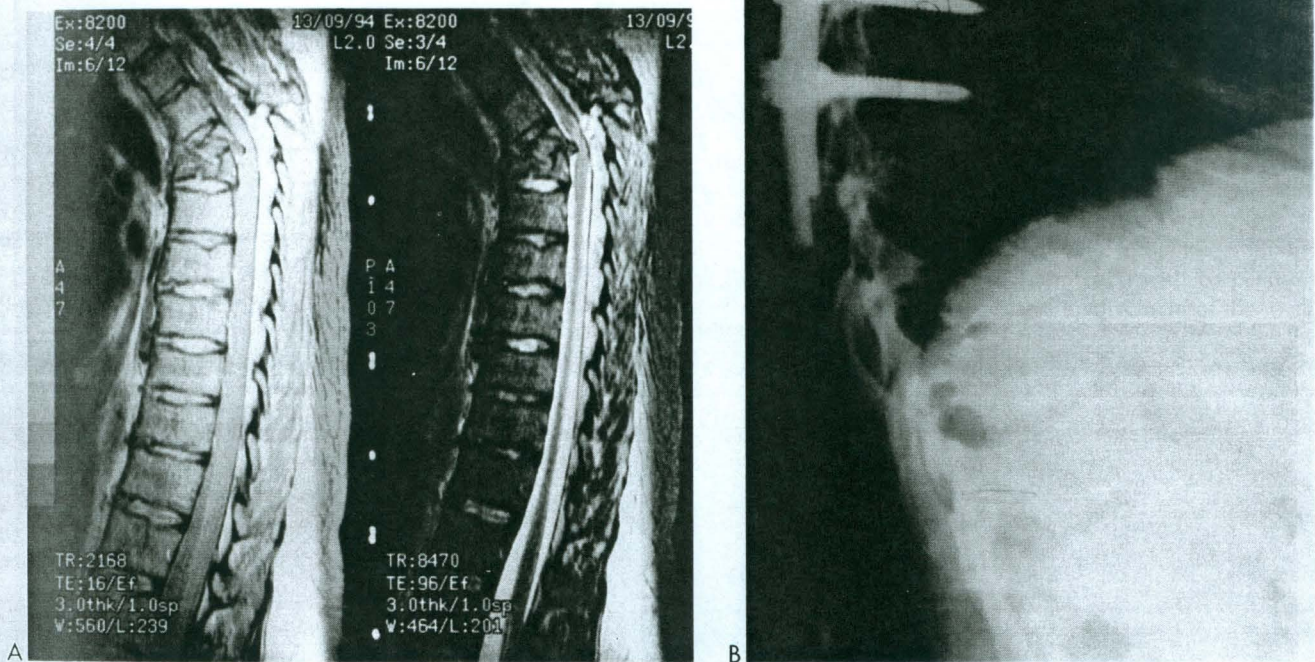


Figure 19.10 (A) Proton density and T₂-weighted sagittal MRI scan showing a T4-T5 fracture dislocation with angulation and spinal cord compression in a 24-year-old woman with an incomplete spinal cord injury. A left third rib thoracotomy approach was used to perform a ventral decompression and reconstruction with rib autograft. In view of the three-column injury with associated rib fractures, posterior instrumentation (AO Universal Spine System) was performed. **(B)** Postoperative lateral radiographs show correction of the kyphotic deformity with posterior segmental stabilization.

the rib cage. However, if there is three-column involvement, additional instrumentation will be necessary (Fig. 19.10).⁶ For the upper thoracic spine (T1 to T3), ventral cervical plates can be used (Fig. 19.11).

T10 to L5

The T12 vertebral body and lumbar spine receive little or no additional support from the rib cage, and in this region there is a greater degree of extension of the spine. Ventral instrumen-

tation is necessary to supplement the reconstruction and to prevent excessive extension that can lead to extrusion of the graft or synthetic construct.^{16,17,21}

Supplemental Ventral Instrumentation

The rationale for using ventral instrumentation can be understood best by considering the biomechanics of the ventral fixation device. Shono et al⁵¹ and Gertzbein¹¹ have described the

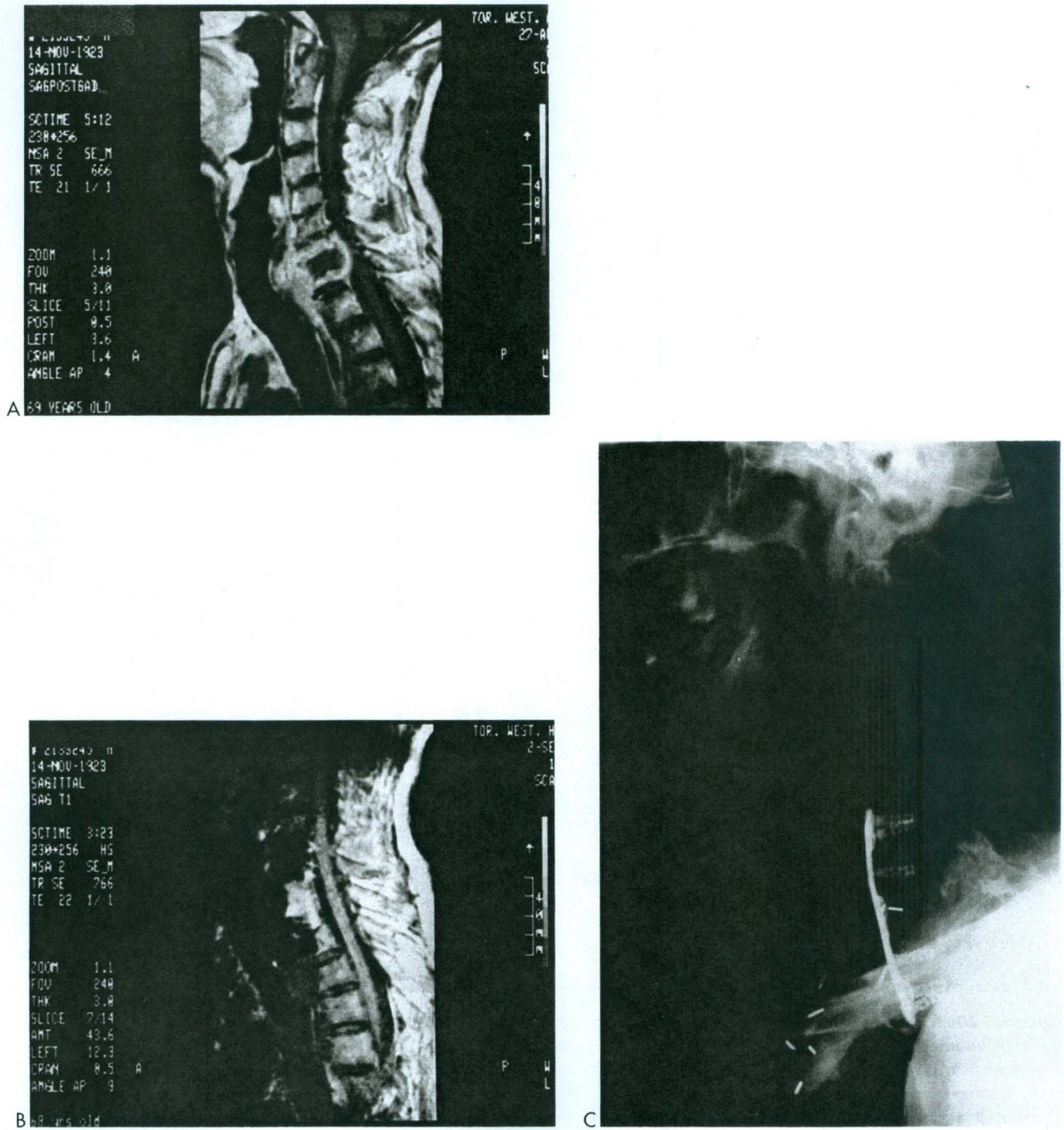


Figure 19.11 (A) Gadolinium-enhanced T₁-weighted sagittal MRI scan of a patient with tuberculosis of the cervicothoracic junction showing vertebral body involvement of T1 and extension into the spinal canal with severe spinal cord compression and paraspinal extension. Surgical exposure of this lesion was achieved via a right-sided cervicosternotomy approach. (B & C) Postoperative T₁-weighted sagittal MRI scan and lateral cervical spine radiograph after vertebral body resection and stabilization with an iliac crest bone graft and Synthes plate.

biomechanics of thoracolumbar ventral fixation devices when loss of anterior and middle column integrity is present. The Kaneda device,¹⁶ which has two cross-fixed rods linked to four vertebral body screws (see Figs. 19.1 and 19.8) allows rigid stabilization against forces of axial compression, flexion, extension, and rotation. The quadrangular construct created by the two independent rods linked by the two cross-fixed bars provides greater resistance to flexion-extension and rotation than a single rod system, such as the Zielke system. The insertion of the vertebral body screws in nonparallel (triangular) alignment controls ventral and downward displacement. In the ventrally destabilized spine, the Kaneda construct provides superior fixation compared with dorsal instrumentation (such as a laminar hook or pedicle screw systems), especially against flexion and axial compression forces. If disruption of dorsal elements is present, ventral instrumentation alone is insufficient to provide stability (see Fig. 19.10). Most important, irrespective of the rigidity of instrumentation, the spinal construct will eventually fail unless solid bony fusion occurs. One of the key concepts of ventral fusion is that the bone graft should be placed under compression to allow greater graft stability and fusion to adjacent vertebral bodies.⁵⁸

Instrumentation Technique

The basic principle entails inserting screws into the midpoint of the vertebral bodies above and below the corpectomy site and connecting these by a rod or plate. Initially Kostuik-Harrington instrumentation was used. This has been supplanted by the Kaneda and Z-plate systems. The Kaneda system is best used between T10 and L4. Above T10, the small size of the vertebral bodies may make screw placement difficult, although the authors have placed the screws as high as T6 in selected cases. Below L4, the iliac veins and origin of the inferior vena cava tend to impede the safe placement of the Kaneda system. The Z-plate system, which has a lower profile, has recently been modified to allow ventral instrumentation of the midthoracic and lower thoracic spine.

OTHER SPINAL PATHOLOGY

In addition to metastatic spinal disease, several other conditions require ventral spinal decompression and are discussed below. Because the principles of ventral spinal decompression, fusion, and instrumentation are similar, only factors that are unique to these situations are outlined.

Osteomyelitis of the Spine

The following are the most common infections of the spinal column: (1) infections caused by pyogenic organisms (*Staphylococcus aureus* and coliform bacilli are the most common pyogenic bacteria found); (2) infections caused by fungi (actinomycetes and blastomycetes are the most common organisms); and (3) tuberculosis (Pott's disease) (see Fig. 19.11).

These organisms usually reach the spinal column by hematogenous spread. Infection becomes symptomatic as a result of

neural compromise from an associated extradural abscess or a bony deformity from vertebral collapse with adjacent bone overgrowth that compromises the spinal canal (gibbus formation). Occasionally, spinal operations can result in osteomyelitis.

Patients with osteomyelitis usually present with back pain, local spinal tenderness, and paraspinal muscle spasm. Associated fever and leukocytosis is common. A characteristic early radiographic finding on lateral and anteroposterior spine films is erosion of several adjacent vertebral bodies with collapse and involvement of associated intervertebral discs. Bone scans are usually positive at regions of vertebral infection and the serum alkaline phosphatase level is often elevated.

In these infective cases, it is important to assess the degree of spinal canal narrowing from vertebral collapse or gibbus formation by using axial CT. In the absence of spinal canal narrowing, an extradural abscess or granuloma is the likely cause of spinal symptoms. MRI or myelography to delineate neural (spinal cord or nerve root) compromise is also indicated in these patients before surgical decompression.

Surgical decompression is indicated in patients with progressive symptoms of spinal cord compression. The thoracic region is the most common site of osteomyelitis, and dorsolateral spinal approaches (e.g., costotransversectomy) usually allow adequate spinal decompression. Occasionally, ventral decompressive procedures are necessary when there is (1) progressive spinal compression; (2) osteomyelitis of the cervical spine; (3) spinal infections with kyphotic angulation in the lower lumbar spine, in which a retroperitoneal approach with corpectomy can be performed; and (4) extensive involvement of the vertebral body that cannot be adequately decompressed by the dorsolateral approach (see Fig. 19.11).

The method of vertebral decompression and reconstruction is similar to that described earlier. The use of autogenous bone is favored in the setting of osteomyelitis. Internal fixation can be used with assurance, even with active infection, provided a good local débridement is achieved. For pyogenic infections, appropriate intravenous antibiotics are necessary for 4 to 6 weeks, followed by oral antibiotics, until the infection resolves both clinically and radiographically. Some patients with tuberculosis of the spine and mild neurologic signs of spinal cord compression improve with antituberculous drugs and rest, without requiring surgical decompression. However, careful, close neurologic follow-up is required to ensure that symptoms are not progressive. It is important to remember that spinal infections can result in spinal cord symptoms without actual spinal cord compression. This occurs as a result of vascular thrombosis secondary to the inflammatory process. It is important, then, to confirm radiologically any evidence of spinal cord compression because these patients do not benefit from surgical decompression.

Kyphotic Deformities

Ventral corpectomy and fusion allow the correction of severe, symptomatic deformities. Surgical exposures are performed as described above, depending on the spinal level of the deformity. A ventral release with section of the anterior longitudinal ligament and discectomies is helpful for correcting the deformity. The adjacent discs involved in the kyphosis are identified

and excised, and autologous bone (cortical iliac bone, section of rib, or even fibula) is used for bone struts. This is supplemented by ventral instrumentation to allow early ambulation of the patient. Most severe fixed kyphotic deformities require supplemental dorsal instrumentation and fusion.

Resection of Hemivertebra

A hemivertebra may become symptomatic and cause a severe, progressive deformity of the spine with neurologic compromise.³² This usually occurs when the anomaly lies low in the lumbar spine and results in congenital scoliosis with the hemivertebra as the apical part of the curve. The hemivertebra is resected ventrally to dorsally, back to the level of the epidural space, with the base of the pedicle also resected. An autologous bony strut graft with ventral instrumentation can be used for stability. A second operation or, at the same setting, a dorsal approach is used to resect the dorsal elements of the hemivertebra.

Thoracic and Thoracolumbar Fractures

These fractures can be approached by a ventral, ventrolateral (see Figs. 19.8 and 19.10), dorsolateral, or dorsal approach depending on certain features.^{4,7,9,23} When lesions are ventral in the thoracic spine, options available for surgical exposure that allow decompression and stabilization include costotransversectomy, a lateral extracavitary approach, a transthoracic extrapleural approach, or a transthoracic transpleural approach. The authors favor the latter approach when neural decompression is an important goal, as in the patient with incomplete spinal cord injury (see Figs. 19.8 and 19.10). For burst fractures at the thoracolumbar junction, a transthoracic/retroperitoneal (tenth rib approach) exposure is used to achieve ventral decompression and reconstruction (see Fig. 19.8). For midlumbar fractures (L2 or L3), a retroperitoneal approach is used. Low lumbar fractures (L4 or L5) are approached via a dorsolateral approach because the nerve roots may be retracted with greater facility to allow easier decompression.

The transthoracic and retroperitoneal approaches allow a single staged procedure with decompression and removal of pathologic material ventral to the dura mater over several vertebral segments and reconstruction with bone graft and instrumentation. Three-column injuries necessitating the use of ventral decompression require supplemental dorsal instrumentation (Fig. 19.10).

DECOMPRESSION AND STABILIZATION Surgical exposures to other thoracic and lumbar levels (T1 to T3 and T3 to L2) are described in Chapters 10 and 11. The fractured or retropulsed bony segment is identified under the microscope and removed using curettes and a high-speed air drill. The intervertebral discs and end-plates of adjacent vertebral bodies are removed to allow adequate fusion of the bony graft inserted between the intact adjacent vertebral bodies above and below the decompression. Certain important principles should be observed in spinal decompression associated with spinal trauma or fractures.

The decompression can often be performed without removing the entire vertebral body. The aim is to remove only the bony segment that is compromising the spinal canal. Using a high-speed burr, this can be performed by drilling away the bone ventral to the bony segment that protrudes into the spinal canal. This creates a vacant area ventral to the bony fragment impinging into the spinal canal.

The retropulsed fragment can then be gently pushed away from the ventral aspect of the dura, using an angled curette, into the empty ventral space. This technique is similar to that used for the removal of a ruptured thoracic disc. For decompressions for fractures, however, one-third to one-half of the vertebral body should be resected to allow adequate spinal decompression.

After a herniated disc or retropulsed bony fragment is removed, the spinal column needs to be stabilized. The segmental vessels of vertebral bodies above and below the fracture dislocation should be suture ligated close to the midline to allow these segments to be instrumented. An adequate subperiosteal dissection of the vertebral body allows the distal side of the vertebral body to be palpated while placing screws so that excessive penetration and thoracic spinal cord injury are avoided. Rib struts, prepared from the resected rib, can be used for the bony graft in the upper thoracic and midthoracic spine. An iliac crest bone graft is used in the lower thoracic spine, thoracolumbar junction, or lumbar spine. Alternatively, allograft humerus or fibula supplemented with local allograft (rib or resected vertebral body) may be used. Subjacent intervertebral discs and cartilaginous end-plates should be removed from vertebral bodies adjacent to the bony graft. Any spinal column deformity that is not fixed should be corrected using an appropriate distraction system. This is particularly useful in cases with significant kyphosis extending over several vertebral levels. Slots are drilled into vertebral bodies immediately above and below the decompression site in order to allow the bone grafts to be held in position. The decompressed vertebral segment is measured and a bone graft of appropriate size is prepared. The bone graft is gently tapped into the prepared lesion between two vertebral bodies using the bone set. A number of instrumentation systems are currently available for ventral instrumentation of the thoracolumbar spine including the Kaneda device, Z-plate, and AO thoracolumbar locking plate.

TRANSTHORACIC DISCECTOMY Symptomatic thoracic intervertebral disc herniations are relatively uncommon, constituting approximately 0.25 to 0.75 percent of all symptomatic disc lesions, and require surgical treatment. They usually occur between T4 and T12. Patients may present with radicular symptoms or spinal cord compression depending on whether the disc has herniated laterally or centrally. Diagnosis is best made using CT or myelogram or, if available, MRI (Fig. 19.12). Initially, thoracic disc herniations were approached by laminectomy with poor results.^{1,19,20,22,24-26,35,36} Although patients with lateral disc herniation fared better than those with central disc herniation, in both cases a number of patients failed to improve, continued to deteriorate, or had postoperative paraparesis as a complication.^{1,19,20,22,24-26,35,36} In 1960, a lateral approach via a costotransversectomy was used with encouraging results.¹⁵ Recently, a more direct ventral transpleural approach has provided further reduction in neurologic morbidity.^{24,25}

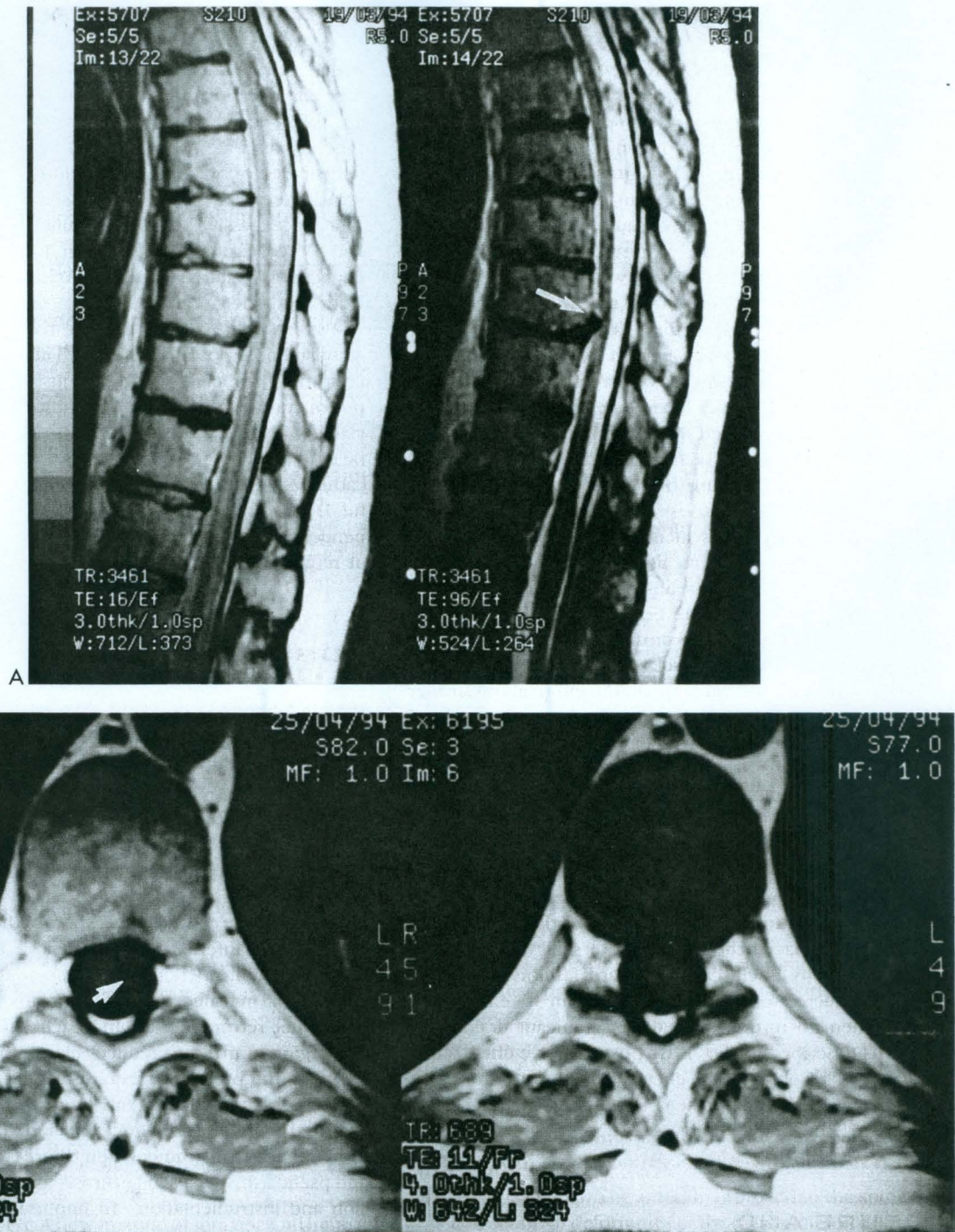


Figure 19.12 (A) Proton density and (B) T₂-weighted sagittal MRI images of a patient with a T9-T10 thoracic disc herniation with spinal cord compression.

TRANSTHORACIC (TRANSPLEURAL) DISCECTOMY This approach allows direct exposure of the ventral and lateral regions of the intervertebral disc. If the surgeon is inexperienced in this approach, exposure should be performed with a thoracic surgeon. The patient's medical and pulmonary condition should be evaluated before surgery to ascertain that the patient is able to tolerate this procedure.

The surgical approach to the appropriate vertebral level by

thoracotomy has been described in Chapter 10. The vertebral bodies above and below the herniated intervertebral disc are identified in the following manner. A given numbered rib articulates with the same numbered vertebral body caudally and the vertebral body above. For example, the eighth rib articulates with the T7 and T8 vertebral bodies and crosses the T7-T8 disc space. Using this principle, the appropriate vertebral level can be identified by placing a needle in the appropriate disc

space and then taking intraoperative radiographs to confirm the appropriate level.

An operating microscope may be used once the appropriate vertebral levels are identified. A sharp linear incision from the upper to the lower vertebral body is made through the parietal pleura and dissected away from the underlying vertebral body to expose the intervertebral elements and the sympathetic chain. The segmental artery and vein, above and below the herniated disc, are ligated and excised as close as possible to the midline to allow adequate exposure of this region. The intercostal nerve is identified and followed to the intervertebral foramen where it is gently retracted to expose the pedicles rostrally and caudally. These pedicles are removed, usually by using a high-speed air drill or a Kerrison rongeur. This exposes the spinal canal and dural sac above and below the herniated disc. The ventral two-thirds of the intervertebral disc, between the vertebral bodies, is incised sharply and removed using pituitary rongeurs and curettes. The herniated disc within the spinal canal is not manipulated during this period. Flexion of the operating table or kidney rest and use of a laminar spreader allow the disc interspace to be further widened. Margins of the vertebral bodies can be removed using an air drill to widen the window exposing the spinal canal. This allows the herniated disc fragments within the spinal canal to be well visualized and to be removed with small curettes and pituitary rongeurs. It is important to avoid retraction or manipulation of the dural sac at this time. To ensure adequate decompression and to allow smaller remnants of herniated disc to be removed, the floor of the spinal canal is palpated gently with flat instruments such as the Penfield dissector, which are then used to gently remove small sequestered disc fragments. If the annulus fibrosus or posterior longitudinal ligament are lax or free, they can be pushed back into the intervertebral space and removed from this region. The operative site is then irrigated, and hemostasis is ensured once the spinal cord appears adequately decompressed. Two chest tubes (# 32 French) to the apex and base of the chest cavity, respectively, are placed through separate skin stab incisions. The thoracic cavity is closed in standard fashion. The chest tubes are connected to an underwater suction system and are removed when no further air leak or significant drainage is observed as described earlier. Early postoperative chest radiographs should be obtained to check for a pneumothorax or pleural effusions, which, if present, should be followed closely with repeated chest radiographs.

CLOSURE AND POSTOPERATIVE CARE

Routine closure with approximation of all muscle layers in surgery involving the thoracic cavity is performed with two thoracostomy tubes, one passing to the apex and one to the dependent region of the chest cavity, connected to an underwater suction seal allowing drainage of air and blood. The drains are removed once the drainage is less than 100 ml over a 12-hour period, which usually occurs by postoperative day 2 or 3. A major complication of both the transpleural and the ventrolateral approaches to the thoracolumbar spine is blood loss. This occurs during both the decompressive procedure and the fusion in which blood loss occurs from the cancellous surfaces

of the bone graft and vertebral body sites. The blood lost should be estimated and should be replaced intraoperatively, and the hematocrit should be followed closely postoperatively. Pulmonary complications are low if relatively young, healthy patients are selected for these procedures.¹¹ Preoperative pulmonary function tests are recommended in patients with a history of lung disease or smoking. In the midthoracic and upper thoracic spine, selective deflation of the ipsilateral lung is recommended to avoid excessive traction. A minimum forced vital capacity and forced expiratory volume in 1 second of 50 percent of expected is required to perform transthoracic surgery with selective lung deflation.

Patients who have undergone transthoracic surgery begin ambulation on postoperative day 3 after removal of tube thoracostomies. Sufficient analgesic must be given at all stages of postoperative care to reduce the postoperative pain that is associated with this type of surgery. Intercostal nerve blocks may be employed before closure of the thoracotomy. Intrathoracic catheters for administration of narcotic analgesics are also helpful. Depending on neurologic recovery and capability for independence and support at home, the patients may return home or require further rehabilitation at an appropriate facility.

COMPLICATIONS

Complications are related to the surgical approach, spinal decompression, and instrumentation. A thoracotomy carries pulmonary risks such as atelectasis and pneumonia. The retroperitoneal exposure may injure the spleen, kidney, or ureter, and a prolonged postoperative ileus may occur. Any unrepaired defect in the abdominal wall or diaphragm may be a site of a later visceral herniation. Using vertebral body screws with manual confirmation of bicortical penetration requires considerable dissection of the contralateral aspect of the vertebral body, placing the aorta, inferior vena cava, and ilio-lumbar vessels at risk if this is not done meticulously. Injury to the lumbar hypogastric plexus at L5 in males may be complicated by retrograde ejaculation. Thus, retroperitoneal approaches to the ventral lumbosacral region in males to reduce this complication is favored.

When the procedure requires decompression of the thecal sac, there remains the potential for neurologic injury. The only reported complications directly related to the Kaneda device are those related to instrumentation failure (screw or rod breakage) and pseudarthrosis. Pseudarthrosis may be treated by dorsal fusion and instrumentation. An important consideration is the avoidance of post-thoracotomy pain, which can be achieved by meticulous dissection of the intercostal neurovascular bundle.

It is important to consider the quality of the patient's bone. Osteoporotic bone provides less mechanical support, increases the risk of an intervening graft penetrating the adjacent vertebral body, reduces the screw-holding power with an increased risk of screw loosening, and slows both bony fusion and healing. Because delayed bone union increases the period of stress on the instrumentation, screw loosening, breakage, and plate migration are all indications of incomplete bony fusion. If incomplete fusion persists, the screws will extrude or fracture. Multilevel fusions place a greater stress on the instrumentation and are at a greater risk for failure. To maximize the chances of attaining a sound construct, it is important to ensure normal

spinal alignment and to attain maximum screw torque. For further support, these procedures should be supplemented with external bracing.

CONCLUSION

Ventral and ventrolateral decompression, fusion, and instrumentation allow adequate spinal canal and spinal cord decompression and provide stability in conditions with loss of anterior and middle column integrity as occurs in trauma (e.g., burst fracture), tumor, infection, degenerative disease, and congenital deformities. The techniques described allow decompression, correction of kyphosis, and stabilization to be performed as a one-stage procedure and provide a stable construct with fixation one level above and below the site of decompression. Postoperatively, excellent results for degree of decompression and rates of fusion have been obtained, with minimal complications related to the surgical procedure.

REFERENCES

- Arseni C, Nash F: Protrusion of thoracic intervertebral discs. *Acta Neurochir (Wien)* 11:1, 1963
- Bernard TN, Whitecloud TS III: Cervical spondylotic myelopathy and myeloradiculopathy— anterior decompression and stabilisation with autogenous fibula strut graft. *Clin Orthop* 221:149, 1987
- Cobden RH, Thrasher EL, Harris WH: Topical hemostatic agents to reduce bleeding from cancellous bone. *J Bone Joint Surg* 58A:70, 1976
- Cook WA: Transthoracic vertebral surgery. *Ann Thorac Surg* 12:54, 1971
- Cooper PR, Errico TJ, Martin R et al: A systematic approach to spinal reconstruction after anterior decompression for neoplastic disease of the thoracic and lumbar spine. *Neurosurgery* 32:1, 1993
- Denis F: Spinal instability as defined by the three-column concept in acute spinal trauma. *Clin Orthop* 189:65, 1984
- Erickson DL, Leider LL, Browne W: One-stage decompression-stabilization for thoracolumbar fractures. *Spine* 2:53, 1977
- Errico TJ, Cooper PR: A new method of thoracic and lumbar body replacement for spinal tumors, technical note. *Neurosurgery* 32:678, 1993
- Flesch JR, Leider LL, Erickson DL et al: Harrington instrumentation and spine fusion for unstable fractures and fracture-dislocations of the thoracic and lumbar spine. *J Bone Joint Surg* 59A:143, 1977
- Geary JR, Frantz VK: New absorbable bone wax. Experimental and clinical studies. *Ann Surg* 132:1128, 1947
- Gertzbein SD, Offerski C: Complete fracture-dislocation of the thoracic spine without spinal cord injury: a case report. *J Bone Joint Surg* 61A:449, 1979
- Hall AJ, Mckay NNS: The results of laminectomy for compression of the cord and cauda equina by extradural malignant tumor. *J Bone Joint Surg* 55B:497, 1973
- Harrington KD: Anterior cord decompression and spinal stabilization for patients with metastatic lesions of the spine. *J Neurosurg* 61:107, 1984
- Hodgson AR, Stock FE: Anterior spinal fusion: a preliminary communication on radical treatment of Pott's disease and Pott's paraplegia. *Br J Surg* 44:266, 1956
- Hulme A: The surgical approach to thoracic intervertebral disc protrusions. *J Neurol Neurosurg Psychiatry* 23:133, 1960
- Kaneda K: Anterior approach and Kaneda instrumentation for lesions of the thoracic and lumbar spine. p. 959. In Bridwell KH, DeWald RL (eds): *The Textbook of Spinal Surgery*. Vol 2. Lippincott-Raven, Philadelphia, 1991
- Kostuik JP, Errico TJ, Gleason TG, Errico CC: Spinal stabilization of vertebral column tumors. *Spine* 13:250, 1988
- Kurz LT, Garfin SR, Booth RE: Iliac bone grafting: techniques of harvesting and complications. p. 323. In Garfin SR (ed): *Complications of Spine Surgery*. Williams & Wilkins, Baltimore, 1989
- Logue V: Thoracic intervertebral disc prolapse with spinal cord compression. *J Neurol Neurosurg Psychiatry* 15:227, 1952
- Love JG, Schorn VG: Thoracic disc protrusions. *JAMA* 191:627, 1965
- Manabe S, Tateishi A, Abe M, Ohno T: Surgical treatment of metastatic tumors of the spine. *Spine* 14:41, 1989
- Mueller R: Prolapse of thoracic intervertebral discs. *Acta Med Scand* 139:99, 1951
- Norrell H: The treatment of unstable spine fractures and dislocations. *Clin Neurosurg* 25:193, 1978
- Perot PL, Munro OD: Transthoracic removal of midline thoracic disc protrusions causing spinal cord compression. *J Neurosurg* 31:452, 1969
- Ransohoff J, Spencer F, Slew F, et al: Transthoracic removal of thoracic disc: report of three cases. *J Neurosurg* 31:459, 1969
- Reeves DL, Brown HA: Thoracic intervertebral disc protrusion with cord compression. *J Neurosurg* 28:24, 1968
- Riseborough EJ: The anterior approach to the spine for the correction of deformities of the axial skeleton. *Clin Orthop* 9:207, 1973
- Royle ND: The operative removal of an accessory vertebra. *Austr Med J* 1:467, 1928
- Sacks S: Anterior interbody fusion of the lumbar spine. *J Bone Joint Surg* 47B:211, 1965
- Sacks S: Anterior interbody fusion of the lumbar spine: indication and results in two hundred cases. *Clin Orthop* 44:163, 1966
- Shono Y, Kaneda K, Yamamoto I: A biomechanical analysis of Zielke, Kaneda, and Cotrel-Dubouset instrumentation in thoracolumbar scoliosis: a calf spine model. *Spine* 16:1305, 1991

32. Slabaugh PB, Winter RB, Lonstein JE, Moe JH: Lumbosacral hemivertebrae: a review of 24 patients, with excision in eight. *Spine* 5:234, 1980
33. Sundaresan N, Galicich JH, Bains MS, et al: Vertebral body resection in the treatment of cancer involving the spine. *Cancer* 53:1393, 1984
34. Sundaresan N, Galicich JH, Lane JM, et al: Treatment of neoplastic epidural spinal cord compression by vertebral body resection and stabilization. *J Neurosurg* 63:676, 1985
35. Svein HJ, Karavitis AL: Multiple protrusions of intervertebral discs in the upper thoracic region: report of case. *Proc Staff Meet Mayo Clin* 29:375, 1954
36. Tovi D, Strang RR: Thoracic intervertebral disc protrusions. *Acta Chir Scand Suppl* 267, 1960
37. White AA, Panjabi MM: *Clinical Biomechanics of the Spine*. Lippincott-Raven, Philadelphia, 1978
38. Wolfe SA, Kawamoto HK: Taking the iliac bone graft: a new technique. *J Bone Joint Surg* 60A:411, 1978
39. Young RF, Post EM, King GA: Treatment of spinal epidural metastases: randomized prospective comparison of laminectomy and radiotherapy. *J Neurosurg* 53:741, 1980